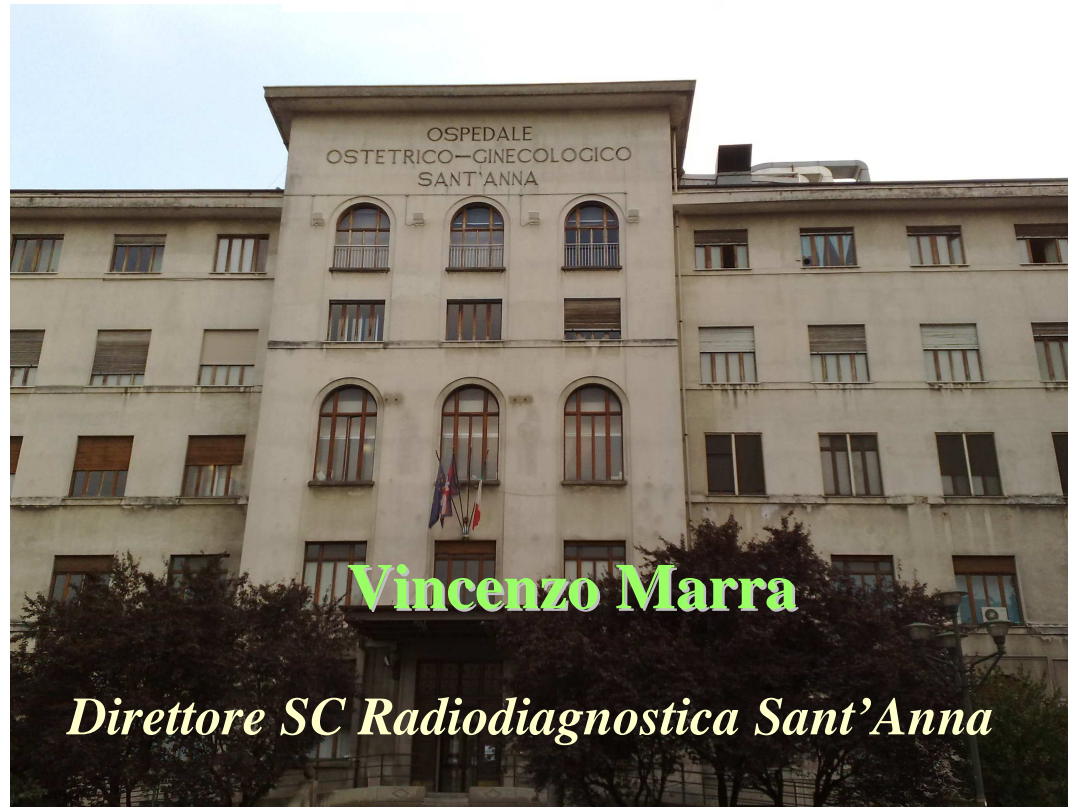

Imaging

aggiornamenti dalla letteratura scientifica



Torino 3 dicembre 2014

PubMed Advanced Search Builder

History deleted.

((Tomosynthesis[Title]) AND Breast[Title/Abstract]) AND Screening[Title/Abstract]

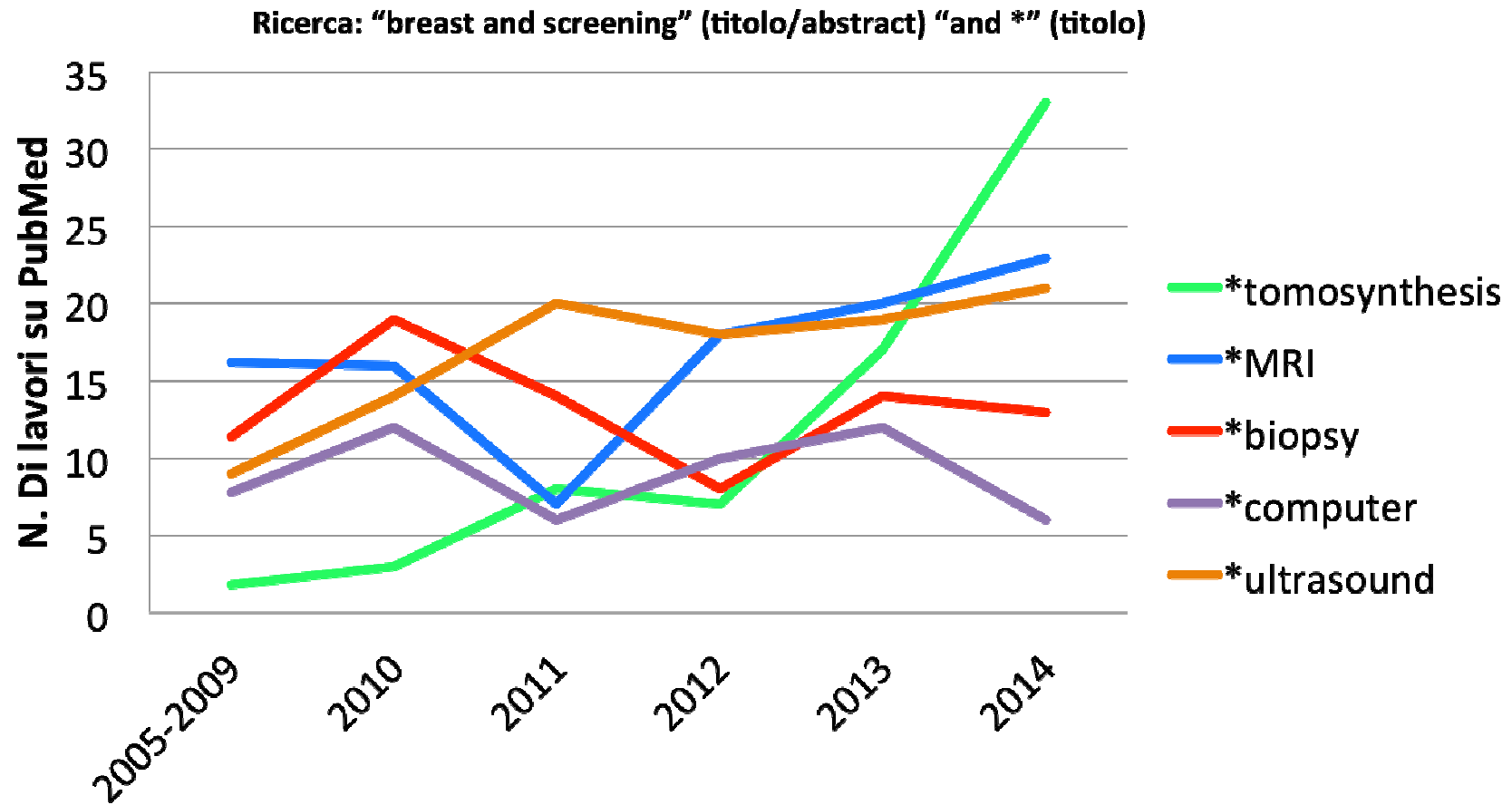
[Edit](#)

Builder

	Title	◇	Tomosynthesis					
AND	◇	Title/Abstract	◇	Breast				
AND	◇	Title/Abstract	◇	Screening				
AND	◇	Date - Publication	◇	YYYY/MM/DD	to	present	−	+

or [Add to history](#)

Publicazioni per anno



- Tomosintesi
- Risonanza Magnetica
- Biopsie
- Computer/Software
- US/Altro

Two-View Digital Breast Tomosynthesis Screening with Synthetically Reconstructed Projection Images: Comparison with Digital Breast Tomosynthesis with Full-Field Digital Mammographic Images¹

Per Skaane, MD, PhD
Andriy I. Bandos, PhD
Ellen B. Eben, MD
Ingvild N. Jebsen, MD
Mona Krager, MD
Unni Haakenaasen, MD
Ulrika Ekseth, MD
Mina Izadi, MD
Solveig Hofvind, PhD
Randi Gullien, RT, MSc

Purpose:

To compare the performance of two versions of reconstructed two-dimensional (2D) images in combination with digital breast tomosynthesis (DBT) versus the performance of standard full-field digital mammography (FFDM) plus DBT.

Materials and Methods:

This trial had ethical committee approval, and all participants gave written informed consent. Examinations ($n = 24901$) in women between the ages of 50 and 69 years (mean age, 59.2 years) were interpreted prospectively as part of a screening trial that included independent in-

Skaane et al, Radiology 2014

MATERIALS AND METHODS:

This trial had ethical committee approval, and all participants gave written informed consent. Examinations (n = 24 901) in women between the ages of 50 and 69 years (mean age, 59.2 years) were interpreted prospectively as part of a screening trial that included independent interpretations of FFDM plus DBT and reconstructed 2D images plus DBT. **Reconstructed 2D images do not require radiation exposure.** Using analyses for binary data that accounted for correlated interpretations and were adjusted for reader-specific volume, two versions (initial and current) of reconstructed 2D images used during trial periods 1 (from November 22, 2010, to December 21, 2011; 12 631 women) and 2 (from January 20, 2012, to December 19, 2012; 12 270 women) were compared in terms of cancer detection and false-positive rates with the corresponding FFDM plus DBT interpretations.

RESULTS:

Cancer detection rates were 8.0, 7.4, 7.8, and 7.7 per 1000 screening examinations for FFDM plus DBT in period 1, initial reconstructed 2D images plus DBT in period 1, FFDM plus DBT in period 2, and current reconstructed 2D images plus DBT in period 2, respectively. False-positive scores were 5.3%, 4.6%, 4.6%, and 4.5%, respectively. Corresponding reader-adjusted paired comparisons of false-positive scores revealed significant differences for period 1 (P = .012) but not for period 2 (ratio = 0.99; 95% confidence interval: 0.88, 1.11; P = .85).

CONCLUSION:

The combination of current reconstructed 2D images and DBT performed comparably to FFDM plus DBT and is adequate for routine clinical use when interpreting screening mammograms.

The accuracy of digital breast tomosynthesis compared with coned compression magnification mammography in the assessment of abnormalities found on mammography.

Morel JC, Iqbal A, Wasan RK, Peacock C, Evans DR, Rahim R, Goligher J, Michell MJ.
Clin Radiol. 2014 Nov;69(11):1112-6. doi: 10.1016/j.crad.2014.06.005. Epub 2014 Aug 3.

AIM: To compare the diagnostic accuracy of the digital breast tomosynthesis (DBT) with coned compression magnification mammography (CCMM).

MATERIALS AND METHODS: The study design included two reading sessions completed by seven experienced radiologists. In the first session, all readers read bilateral standard two-view mammograms and a CCMM view of the lesion before giving a combined score for assessment. In the second session, readers read bilateral standard two-view mammograms plus one-view DBT. The two reading sessions of the experiment were separated by at least 2 weeks to reduce the chance of reader memory of the images read in the previous session from influencing the performance in the subsequent session.

RESULTS: Three hundred and fifty-four lesions were assessed and receiver-operative characteristic (ROC) analysis was used to evaluate the difference between the two modes. For standard two-view mammography plus CCMM, the area under the curve (AUC) was 0.87 [95% confidence interval (CI): 0.83-0.91] and for standard two-view mammography plus DBT the AUC was 0.93 (95% CI: 0.91-0.95). The difference between the AUCs was 0.06 with p-value of 0.0014.

CONCLUSION: Two-view mammography with one-view DBT showed significantly improved accuracy compared to two-view mammography and CCMM in the assessment of mammographic abnormalities. These results show that DBT can be used effectively in the further evaluation of mammographic abnormalities found at screening and in symptomatic diagnostic practice.

- Tomosintesi
- **Risonanza Magnetica**
- Biopsie
- Computer/Software
- US/Altro

MRI breast screening in high-risk women: cancer detection and survival analysis

Evans D. Gareth · Kesavan Nisha · Lim Yit · Gadde Soujanya · Hurley Emma ·
Nathalie J. Massat · Anthony J. Maxwell · Ingham Sarah · Eeles Rosalind ·
Martin O. Leach · MARIBS Group · Howell Anthony · Duffy Stephen

Women with a genetic predisposition to breast cancer tend to develop the disease at a younger age with denser breasts making mammography screening less effective. The introduction of magnetic resonance imaging (MRI) for familial breast cancer screening programs in recent years was intended to improve outcomes in these women. We aimed to assess whether introduction of MRI surveillance improves 5- and 10-year survival of high-risk women and determine the accuracy of MRI breast cancer detection compared with mammography-only or no enhanced surveillance and compare size and pathology of cancers detected in women screened with MRI + mammography and mammography only. We used data from two prospective studies where asymptomatic women with a very high breast cancer risk were screened by either mammography alone or with MRI also compared with BRCA1/2 carriers with no intensive surveillance. 63 cancers were detected in women receiving MRI + mammography and 76 in women receiving mammography only. Sensitivity of MRI + mammography was 93% with 63% specificity. Fewer cancers detected on MRI were lymph node positive compared to mammography/no additional screening. **There were no differences in 10-year survival between the MRI + mammography and mammography- only groups**, but survival was significantly higher in the MRI-screened group (95.3 %) compared to no intensive screening (73.7 %; $p = 0.002$). There were no deaths among the 21 BRCA2 carriers receiving MRI. **There appears to be benefit from screening with MRI, particularly in BRCA2 carriers**. Extended follow-up of larger numbers of high-risk women is required to assess long-term survival.

Abbreviated Breast Magnetic Resonance Imaging (MRI): First Postcontrast Subtracted Images and Maximum-Intensity Projection—A Novel Approach to Breast Cancer Screening With MRI

Christiane K. Kuhl, Simone Schrading, Kevin Strobel, Hans H. Schild, Ralf-Dieter Hilgers, and Heribert B. Bieling

Purpose: We investigated whether an abbreviated protocol (AP), consisting of **only one pre- and one postcontrast acquisition and their derived images** (first postcontrast subtracted [FAST] and maximum-intensity projection [MIP] images), was suitable for breast magnetic resonance imaging (MRI) screening.

Methods: We conducted a prospective observational reader study in 443 women at mildly to moderately increased risk who underwent 606 screening MRIs. Eligible women had normal or benign digital mammograms and, for those with heterogeneously dense or extremely dense breasts ($n \square 427$), normal or benign ultrasounds. Expert radiologists reviewed the MIP image first to search for significant enhancement and then reviewed the complete AP (consisting of MIP and FAST images and optionally their nonsubtracted source images) to characterize enhancement and establish a diagnosis. Only thereafter was the regular full diagnostic protocol (FDP) analyzed.

Kuhl et al, J Clin Oncol 2014

Results

MRI acquisition time for FDP was 17 minutes, versus 3 minutes for the AP. Average time to read the single MIP and complete AP was 2.8 and 28 seconds, respectively. Eleven breast cancers (four ductal carcinomas in situ and seven invasive cancers; all T1N0 intermediate or high grade) were diagnosed, for an additional cancer yield of 18.2 per 1,000. MIP readings were positive in 10 (90.9%) of 11 cancers and allowed establishment of the absence of breast cancer, with a negative predictive value (NPV) of 99.8% (418 of 419). Interpretation of the complete AP, as with the FDP, allowed diagnosis of all cancers (11 [100%] of 11). Specificity and positive predictive value (PPV) of AP versus FDP were equivalent (94.3% v 93.9% and 24.4% v 23.4%, respectively).

Conclusion

An MRI acquisition time of 3 minutes and an expert radiologist MIP image reading time of 3 seconds are sufficient to establish the absence of breast cancer, with an NPV of 99.8%. With a reading time \leq 30 seconds for the complete AP, diagnostic accuracy was equivalent to that of the FDP and resulted in an additional cancer yield of 18.2 per 1,000.

In conclusion, our study suggests that with the abbreviated breast MRI approach presented here, screening breast MRI is feasible without compromising sensitivity or specificity compared with the regular full diagnostic MRI protocol. Abbreviated breast MRI screening could thus open up the opportunity for batch MRI screening according to the model of mammographic screening. If confirmed by future trials, this could increase access to breast MRI and decrease the cost of existing MRI screening programs.

- Tomosintesi
- Risonanza Magnetica
- **Biopsie**
- Computer/Software
- US/Altro

Digital Breast Tomosynthesis-guided Vacuum-assisted Breast Biopsy: Initial Experiences and Comparison with Prone Stereotactic Vacuum-assisted Biopsy.

Schrading S¹, Distelmaier M, Dirrichs T, Detering S, Brolund L, Strobel K, Kuhl CK.

+ Author information

Abstract

Purpose To use digital breast tomosynthesis (DBT digital breast tomosynthesis)-guided vacuum-assisted biopsy (VAB vacuum-assisted biopsy) to sample target lesions identified at full-field digital screening mammography and compare clinical performance with that of prone stereotactic (PS prone stereotactic) VAB vacuum-assisted biopsy . **Materials and Methods** In this institutional review board-approved study, 205 patients with 216 mammographic findings suspicious for cancer were scheduled to undergo mammography-guided VAB vacuum-assisted biopsy . Written informed consent was obtained. PS prone stereotactic VAB vacuum-assisted biopsy was performed in 159 patients with 165 target lesions. DBT digital breast tomosynthesis VAB vacuum-assisted biopsy was performed in 46 consecutive patients with 51 target lesions. Tissue-sampling methods and materials (9-gauge needles) were the same with both systems. For calcifications, specimen radiographs were obtained, and for masses or architectural distortions, control mammography or DBT digital breast tomosynthesis was performed to confirm adequate target lesion sampling. χ^2 and Student t tests were used to compare biopsy time, and the Fisher exact test was used to compare lesion type distribution for DBT digital breast tomosynthesis versus PS prone stereotactic VAB vacuum-assisted biopsy . **Results** Technical success was achieved in 51 of 51 lesions (100%) with DBT digital breast tomosynthesis VAB vacuum-assisted biopsy versus 154 of 165 lesions (93%) with PS prone stereotactic VAB vacuum-assisted biopsy . In one of 11 lesions in which PS prone stereotactic VAB vacuum-assisted biopsy failed, DBT digital breast tomosynthesis VAB vacuum-assisted biopsy was performed successfully. Mean time to complete VAB vacuum-assisted biopsy was 13 minutes \pm 3.7 for DBT digital breast tomosynthesis VAB vacuum-assisted biopsy versus 29 minutes \pm 10.1 for PS prone stereotactic VAB vacuum-assisted biopsy (P < .0001). Reidentifying and targeting lesions during PS prone stereotactic VAB vacuum-assisted biopsy took longer than it did during DBT digital breast tomosynthesis VAB vacuum-assisted biopsy (P < .0001). Tissue sampling took about the same time for PS prone stereotactic VAB vacuum-assisted biopsy and DBT digital breast tomosynthesis VAB vacuum-assisted biopsy (P = .067). Significantly more "low-contrast" (ie, uncalcified) target lesions were biopsied with DBT digital breast tomosynthesis VAB vacuum-assisted biopsy (13 of 51 lesions) versus PS prone stereotactic VAB vacuum-assisted biopsy (nine of 165 lesions) (P < .0002). No major complications were observed with either system. One patient who underwent DBT digital breast tomosynthesis VAB vacuum-assisted biopsy in the sitting position and one patient who underwent PS prone stereotactic VAB vacuum-assisted biopsy developed self-limiting vasovagal reactions. **Conclusion** Clinical performance of DBT digital breast tomosynthesis VAB vacuum-assisted biopsy was significantly superior to PS prone stereotactic VAB vacuum-assisted biopsy . Because DBT digital breast tomosynthesis VAB vacuum-assisted biopsy allows use of the full detector size for imaging and provides immediate lesion depth information without requiring triangulation, it facilitates target lesion reidentification and sampling of even low-contrast targets, such as uncalcified masses. © RSNA, 2014 Online supplemental material is available for this article.

- Tomosintesi
- Risonanza Magnetica
- Biopsie
- **Computer/Software**
- US/Altro



Single reading with computer-aided detection performed by selected radiologists in a breast cancer screening program



Xavier Bargalló^{a,*}, Gorane Santamaría^a, Montse del Amo^a, Pedro Arguis^a, José Ríos^c,
Jaume Grau^b, Marta Burrel^a, Enrique Cores^a, Martín Velasco^a

^a Department of Radiology (CDIC), Hospital Clínic de Barcelona, C/ Villarroel, 170, 08036 Barcelona, Spain

^b Preventive Medicine and Epidemiology Unit, Hospital Clínic de Barcelona, C/ Villarroel, 170, 08036 Barcelona, Spain

^c Biostatistics and Data Management Core Facility, IDIBAPS, (Hospital Clínic) C/ Mallorca, 183. Floor -1. Office #60. 08036 Barcelona, Spain

ARTICLE INFO

Article history:

Received 11 July 2014

Accepted 13 August 2014

Keywords:

Mammography

Breast screening

Breast neoplasms

Computer-assisted diagnosis

Breast

ABSTRACT

Objectives: To assess the impact of shifting from a standard double reading plus arbitration protocol to a single reading by experienced radiologists assisted by computer-aided detection (CAD) in a breast cancer screening program.

Methods: This was a prospective study approved by the ethics committee. Data from 21,321 consecutive screening mammograms in incident rounds (2010–2012) were read following a single reading plus CAD protocol and compared with data from 47,462 consecutive screening mammograms in incident rounds (2004–2010) that were interpreted following a double reading plus arbitration protocol. For the single reading, radiologists were selected on the basis of the appraisalment of their previous performance.

Results: Period 2010–2012 vs. period 2004–2010: Cancer detection rate (CDR): 6.1% (95% confidence interval: 5.1–7.2) vs. 5.25%; Recall rate (RR): 7.02% (95% confidence interval: 6.7–7.4) vs. 7.24% (selected readers before arbitration) and vs. 3.94 (all readers after arbitration); Predictive positive value of recall: 8.69% vs. 13.32%. Average size of invasive cancers: 14.6 ± 9.5 mm vs. 14.3 ± 9.5 mm. Stage: 0 (22.3/26.1%); I (59.2/50.8%); II (19.2/17.1%); III (3.1/3.3%); IV (0/1.9%). Specialized breast radiologists performed better than general radiologists.

Conclusions: The cancer detection rate of the screening program improved using a single reading protocol by experienced radiologists assisted by CAD, at the cost of a moderate increase of the recall rate mainly related to the lack of arbitration.

- Tomosintesi
- Risonanza Magnetica
- Biopsie
- Computer/Software
- US/Altro

Contrast-enhanced spectral mammography in patients referred from the breast cancer screening programme.

Lobbes MB¹, Lalji U, Houwens J, Nijssen EC, Nelemans PJ, van Roozendaal L, Smidt ML, Heuts E, Wildberger JE.

Author information

¹Department of Radiology, Maastricht University Medical Center, P.O. Box 5800, 6202 AZ, Maastricht, The Netherlands, marc.lobbes@mumc.nl.

Abstract

OBJECTIVES: Feasibility studies have shown that contrast-enhanced spectral mammography (CESM) increases diagnostic accuracy of mammography. We studied diagnostic accuracy of CESM in patients referred from the breast cancer screening programme, who have a lower disease prevalence than previously published papers on CESM.

METHODS: During 6 months, all women referred to our hospital were eligible for CESM. Two radiologists blinded to the final diagnosis provided BI-RADS classifications for conventional mammography and CESM. Statistical significance of differences between mammography and CESM was calculated using McNemar's test. Receiver operating characteristic (ROC) curves were constructed for both imaging modalities.

RESULTS: Of the 116 eligible women, 113 underwent CESM. CESM increased sensitivity to 100.0% (+3.1%), specificity to 87.7% (+45.7%), PPV to 76.2% (+36.5%) and NPV to 100.0% (+2.9%) as compared to mammography. Differences between conventional mammography and CESM were statistically significant ($p < 0.0001$). A similar trend was observed in the ROC curve. For conventional mammography, AUC was 0.779. With CESM, AUC increased to 0.976 ($p < 0.0001$). In addition, good agreement between tumour diameters measured using CESM, breast MRI and histopathology was observed.

CONCLUSION: CESM increases diagnostic performance of conventional mammography, even in lower prevalence patient populations such as referrals from breast cancer screening.

KEY POINTS: • CESM is feasible in the workflow of referrals from routine breast screening. • CESM is superior to mammography, even in low disease prevalence populations. • CESM has an extremely high negative predictive value for breast cancer. • CESM is comparable to MRI in assessment of breast cancer extent. • CESM is comparable to histopathology in assessment of breast cancer extent.

Interpretation of automated breast ultrasound (ABUS) with and without knowledge of mammography: a reader performance study.

Skaane P, Gullien R, Eben EB, Sandhaug M, Schulz-Wendtland R, Stoeblen F.
Acta Radiol. 2014 Mar 28. pii: 0284185114528835. [Epub ahead of print]

BACKGROUND: Automated breast ultrasonography (ABUS) has the potential to be an important adjunct to mammography in women with dense breasts.

PURPOSE: To compare reader performance and inter-observer variation of ABUS alone and in combination with mammography.

MATERIAL AND METHODS: This retrospective study had ethical committee approval. All women gave written informed consent. 114 breasts in 90 women examined by digital mammography and ABUS were interpreted by five radiologists using BI-RADS categories. The 114 breasts included 38 cancers and 76 normal or benign findings. In the first reading session ABUS only was interpreted, and in the second ABUS plus digital mammography. Image interpretations were done without knowledge of clinical or imaging results. A consensus panel analyzed false negative and false positive interpretations. Reading time was recorded for one radiologist. AUC was used for performance measurement, and kappa statistic for inter-observer variability.

RESULTS: Mean size for cancers was 16.2mm; area under the curve (AUC) values for ABUS alone and for combined reading were, respectively: reader A, 0.592-0.744; reader B, 0.740-0.947; reader, C 0.759-0.823; reader D, 0.670-0.688; reader E, 0.904-0.923; and all readers combined 0.730-0.823. The higher AUC for combined reading was statistically significant ($P < 0.05$) for reader B and for all readers. There was a considerable inter-observer variability. Observer agreement revealed following kappa values for ABUS alone and combined reading, respectively: reader A, 0.22-0.30; reader B, 0.33-0.44; reader C, 0.32-0.39; reader D, 0.07-0.14; and reader E, 0.34-0.43. Shadowing from dense parenchyma was the most common cause of false positive ABUS interpretations. Mean interpretation time for a bilateral normal ABUS examination was 9min.

CONCLUSION: Observer agreement was higher and all radiologists improved diagnostic performance using combined ABUS and mammography interpretation. Combined reading should be standard if ABUS is implemented in screening of women with dense breasts.

Grazie per l'Attenzione!

vmarra@cittadellasalute.to.it